


Clinical and cost-effective benefit of new magnetic ureteral stent **Magnetic Black-Star®**: results in a single center study

Case Report, 2022



Dott. Daniele Maruzzi, MD
Responsabile „S.S. Endourologia e tecniche endoscopiche mini invasive“
Dipartimento di Chirurgia Generale
Ospedale Santa Maria degli Angelini,
Pordenone



Dott. Francesco Visalli
Dirigente Medico presso
S.O.C. Urologia
U.L.S.S. 2 Marca Trevigiana -
Ospedale di Conegliano



Introduction

Ureteral stents are commonly used in urology to remove the obstruction caused by urinary stones. Their positioning keeps the ureteral lumen open and thus facilitates the drainage of urine from the kidney to the bladder (1).

The first ureteral stents were described in the literature starting in 1949 (2) and were made from polyethylene. Due to the high rate of encrustation and thanks to the technological development in the field of prosthetic devices, polyethylene was soon replaced by materials such as silicone and polyurethane.

However, in the 1970's, due to frequent migration episodes and the high rate of intolerance to these devices, double-J ureteral stents were introduced (3).

Currently, it is not yet proven whether the use of the ureteral stent is necessary at the end of endoscopic procedures (or endourology) dedicated to the treatment of urinary stones.

The choice to use a ureteral stent depends on numbers of variables: surgery duration, intraoperative complications, patient anatomy, size, location and hardness of the stone (4).

These aspects would be at the basis of the parietal edema which determines the obstruction of the ureteral lumen following the endoscopic procedure. Nevertheless, in the literature (5), there is a lower incidence of new hospital admissions and complications for stented patients in comparison with "tubeless" patients. In conclusion the decision remains subjective.

One of the main problems of ureteral stents is the appearance of lower urinary tract symptoms (LUTS) such as urgency, dysuria or hematuria. Moreover, their removal requires flexible cystoscopy, with consequent infectious disease risk.

In 2013, Urotech GmbH, Germany, launched a newly and very innovative magnetic ureteral stent, the Magnetic Black Star®. Made of polyurethane, this double J stent is different of the others as it contains a magnet at the distal end intended to a easy retrieval of the stent with an associated magnetic device and without any cystoscopy.

The primary objective of this study was to verify the usefulness of the magnetic ureteral stent in patients undergoing endourological procedures. The secondary objective was to analyze its tolerability during the time of implantation.



Material and Methods

From January 2017 until October 2021, 138 consecutive patients from Hospital Santa Maria degli Angeli in Pordenone, Italy, underwent an endourological procedure that required the placement of a stent, in this case a magnetic ureteral stent (Magnetic Black-Star®, Urotech).

At the time of surgery, the median age of the patients was 53.8 years (19-86). All of them were treated due to urolithiasis.

The characteristics of this device have been well described by Rassweiler et al (6).

In particular, it is emphasized the presence of a small magnet connected to the distal coil of the stent. Its removal takes place using a special retrieval device, which is inserted trans-urethral, without the aid of a flexible cystoscope.

In most cases, the ureteral stent was positioned to avoid the occurrence of ureteral obstruction secondary to the urinary stones or to the post-surgical parietal edema. In one patient a stent was placed after renal trauma with rupture of the excretory path.

Mainly, the purpose of the treatment was the urinary tract derivation following obstruction from urinary stones or after the lithotripsy of the urinary stones.

In only one case, the ureteral stent was placed with the aim of removing the upper urinary tract obstruction caused by ureteral stones.

In the rest, the device was placed at the end of an endourological procedure: 131 retrograde intrarenal surgery/ureterorenoscopies (RIRS/URS) and 6 percutaneous nephrolithotripsies/endoscopic combined intrarenal surgeries (PCNL/ECIRS).

In all these patients, the aim of the treatment was the fragmentation of urinary stones (renal, ureteral, both) with laser energy, and their removal was then obtained using a stone basket.

The subsequent removal of the Magnetic Black-Star® was planned upon discharge and was performed by nursing staff on an outpatient basis with the aid of the appropriate magnetic retrieval device.

Results

We performed 138 endourological procedures. We obtained the complete removal of urinary stones in 79.7% of cases (110/138).

Based on the anatomical characteristics, different measures were used to determine the most appropriate stent, both for diameter and for length, as described in table 1.

A delicate moment of the procedure is given by the insertion of the distal coil in the bladder, including the small magnet. The latter, if not correctly introduced into the bladder, can be attached to the cystoscope with consequent displacement of the stent itself.

In 3 cases, the retrieval device did not allow the removal of the stent. In these patients we achieved the goal successfully using a flexible cystoscope. These patients

actually showed a modified anatomy of the lower urinary tract (previous urethral stricture subjected to urethroplasty, large prostatic hypertrophy with third lobe projecting into the bladder). None referred pain or LUTS after the removal of the stent nor medical treatments were employed.

On average, the patients maintained the stent for a period of 22.4 days (6-78).

Patients who reported poor tolerance (11/138, 8%) presented: fever (3/138), urgency (6/138) and hematuria (2/138). They received antibiotic therapy when suspected urinary tract infection (UTI) and pain killers or anticholinergic drugs in the other cases.

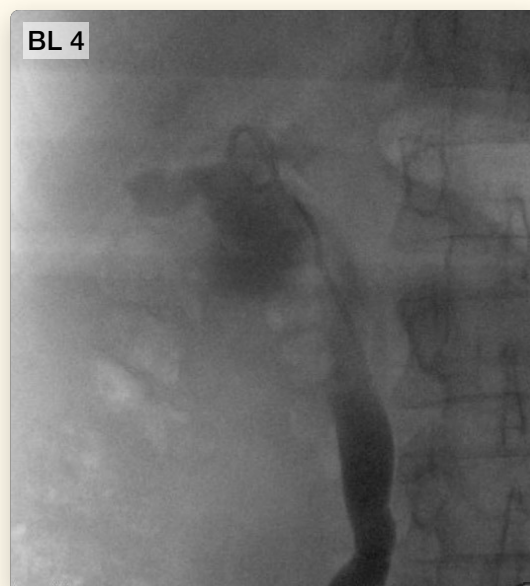
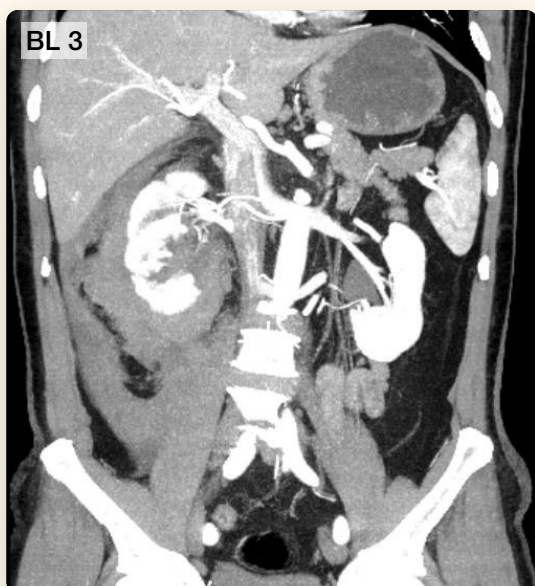
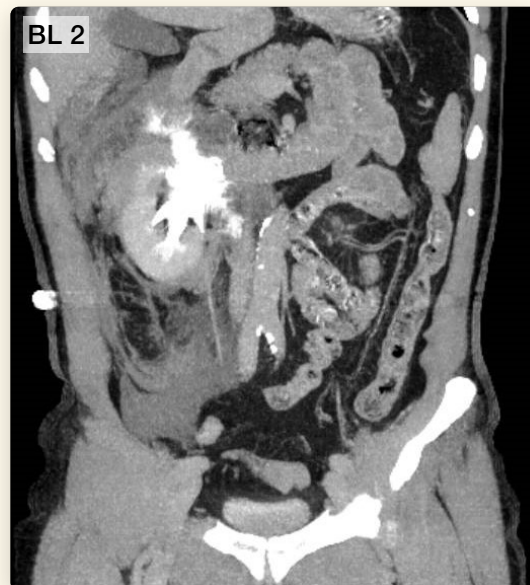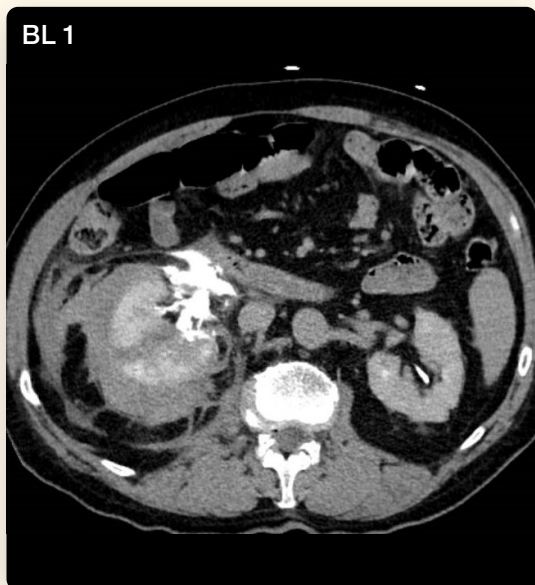None of the stents presented encrustations upon removal.

Table 1: Characteristics of patients, procedures and associated devices

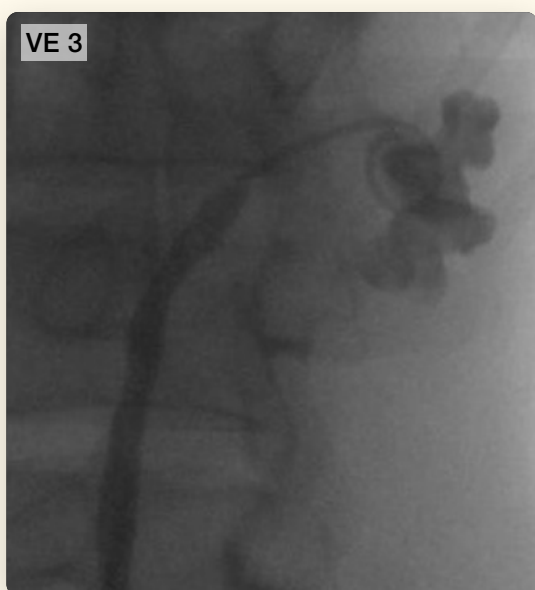
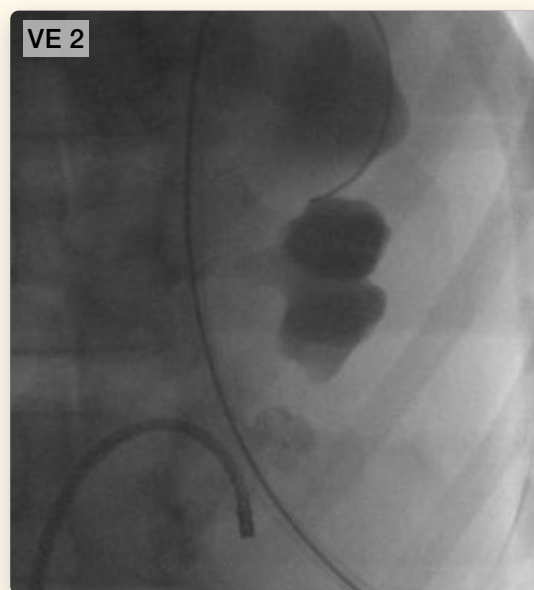
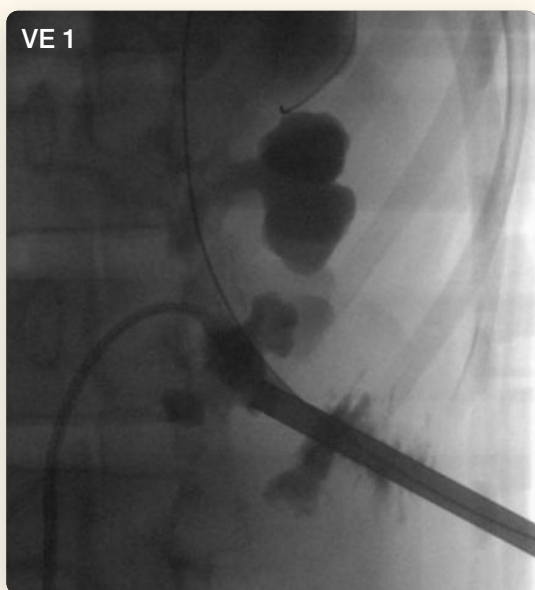
Magnetic Black-Star®	
Patients (n°)	138
Median age (anni)	53,8 (19-86)
Diameter Magnetic Black-Star® (n°)	
4,8 Ch	1
6 Ch	137
Lenght Magnetic Black-Star® (n°)	
24cm	68
26cm	69
28cm	1
Median residence time (giorni)	22,4 (6-78)
Associated procedure	
PCNL	6
RIRS/URS	131
Stenting ureterale	1
Complications	
Fever	3
Urgency	6
Haematuria	2
Difficult removal	
Yes	3
No	135

Specifically, we describe two particular cases below.

The first patient, B.L., a 68 year-old man, went to the emergency room for abdominal pain and hematuria following a fall while he was skiing. CT-scan showed a grade IV right kidney trauma with rupture of the excretory path (see photos BL 1, BL 2, BL 3). For this reason it was necessary to place a Magnetic Black-Star® stent 6Chx26cm (see photo BL 4). After 62 days, the stent was successfully removed on an outpatient basis with the sole aid of the retrieval device.



The second patient, V.E., a 68 year-old man, underwent endourological surgery of “tubeless” mini-Endoscopic Combined Intrarenal Surgery (mini-ECIRS) for multiple pyelic and lower calyceal stones (respectively of 14x10mm, 15x10mm, 12x8mm – 450 Hounsfield Unit) on the left kidney. The procedure lasted 110 minutes using a 7.5Fr flexible ureterorenoscope and a 7.5Fr mininephroscope. The stones were fragmented by laser energy and the fragments were removed using a stone basket. At the end, a Magnetic Black-Star® stent 6Chx24cm was placed (see photos VE 1, VE 2, VE 3). After 37 days, the stent was successfully removed on an outpatient basis with the sole aid of the retrieval device.



Discussion

Ureteral stenting in urology has an increasingly important role, in particular due to the need to derive the upper urinary tract following an obstruction from urolithiasis (associated or not with sepsis) or at the end of endourological procedures.

Like all foreign bodies, ureteral stents also suffer from limits related to patient tolerability and prolonged contact with urine (1;7). LUTS (hematuria, dysuria, urgency, abdominal pain) occur with an incidence proportional to the indwelling time (7;8). Similarly, the bacterial contamination process and the encrustation occur in proportion to the period of exposure to the components present within the urine. In fact, it has been shown that, after 6 weeks, the encrustation percentage is 9%. This value increases to 48% after 6-12 weeks, and up to 77% if the stent remains in the body beyond 12 weeks (9).

Over the decades, significant research have been published regarding ureteral stents and have highlighted the results obtained using different kinds of devices based on materials (hydrophilicity, hardness), diameter-length and coil design (9-11). In general, none of these technological progresses has shown a significant improvement (in terms of tolerability and encrustation) in favor of one stent over the other (12).

In our study, the Magnetic Black-Star® ureteral stent was used. It is made of polyurethane. A small magnetic device is connected to its distal coil which allows the removal of the stent using a special retrieval device via the trans-urethral route, without any cystoscopy.

This aspect is advantageous for two reasons: first, because it reduces the risk of UTI secondary to endoscopic proce-

dures and second, for a purely economic reason. In fact, despite the Magnetic Black-Star® is more expensive than a conventional stent, there is a considerable cost saving by avoiding the physician, nursing, and processing fees of cystoscopy. This saving per patient amounts to \$ 238 (13).

On average, patients kept the stent in place for a relatively short period (22 days). Over this time frame, only a small number of subjects (11/138) referred LUTS. Previously, Rassweiler et al. (7) showed a higher number of LUTS (48% abdominal pain), on a slight number of patients. They explained that this event could be related to the presence of the magnet inside the bladder. On the contrary, Kapoor et al. (13) did not observe statistically significant differences in terms of tolerability between Magnetic Black Star® and conventional stent.

The good tolerability described in our serie could be related to the specific material of Urotech's stents. Thanks to HybridPRO material, these stents seem to have a low inflammatory effect: stents appear stiff at insertion and then become softer at the temperature of the body (37°C), likely to reduce discomfort and stent-related symptoms.

Koprowski et al (1) described complaints with other kinds of stent in a large number of patients (32-80%). Those symptoms required the removal of the device itself. Similarly, our study demonstrated that Magnetic Black-Star® stent is safe, with a high tolerability rate.

In our study, no case of encrustation was reported at the time of stent removal.

Furthermore, cystoscopy for stent removal was only necessary in 3 cases.

Conclusion

In patients who undergo any surgery for the treatment of urinary stones, the use of Magnetic Black-Star® ureteral stent is safe, effective, and easy to apply.

The tolerability in the short to medium-term proved to be optimal, with a limited number of side effects.

In particular, its removal with the use of its retrieval device significantly reduces the costs related to the employment of endoscopic instruments (cystoscope) and the risk of consequent urinary infection.

References

1. Koprowski C et al. "Ureteral stent-associated pain: a review" J Endourol (2016); Vol 30 (7): 744-53
2. Herdman JP et al. "Polythene tubing in the experimental surgery of the ureter" Br J Surg (1949); Vol 37(145): 105
3. Williams KG et al. "Ureteric stents: the past, present and future" J Clin Urol (2018); Vol 11(4): 280-4
4. Sali GM et al. "Ureteric stents: overview of current clinical applications and economic implications" Int J Urol (2020); Vol 27(1): 7-15
5. Wang H et al. "Meta-analysis of stenting versus non-stenting for the treatment of ureteral stones" PLoS One (2017); Vol 9;12(1): e0167670
6. Rassweiler MC et al. "Magnetic ureteral stent removal without cystoscopy: a randomized controlled trial" J Endourol (2017); 31(8): 762-6
7. Torrecilla C et al. "Reduction of ureteral stent encrustation modulating the urine pH and inhibiting the crystal film with a new oral composition: a multicenter, controlled, double blind, randomized clinical trial" BMC Urol (2020); Vol 20: 65
8. Wiseman O et al. "Effects of silicone hydrocoated double loop ureteral stent on symptoms and quality of life in patients undergoing flexible ureteroscopy for kidney stones: a randomized multicenter clinical study" J Urol (2020); Vol 204: 769-77
9. Tomer N et al. "Ureteral stent encrustation: epidemiology, pathophysiology, management and current technology" J Urol (2021); Vol 205(1): 68-77
10. Forbes C et al. "Innovations in ureteral stent technology" Urol Clin North Am (2019); Vol 46(2): 245-55
11. Lundeen CJ et al. "Ureteral stents: the good the bad and the ugly" Curr Opin Urol (2020); Vol 30(2): 166-70
12. Mosayyebi A et al. "Advances in ureteral stent design and materials" Curr Urol Rep (2018); Vol 19(5): 35
13. Kapoor A et al. "Comparison of a magnetic retrieval device vs. flexible cystoscopy for removal of ureteral stents in renal transplants patients: a randomized controlled trial" Can Urol Assoc J (2021); Vol 15(2): E97-102

UROTECH GmbH

Medi-Globe-Strasse 1-5
D-83101 Rohrdorf/Achenmühle
Phone: +49 (0) 8032 973-210
Fax: +49 (0) 8032 973-211
Email: info@urotech.com
www.urovision-urotech.com